

CLINICAL TECHNIQUES AND TECHNOLOGY

Building a real endoscopic sinus and skull-base surgery simulator

João Flávio Nogueira, MD, Aldo Cassol Stamm, MD, PhD, Marcos Lyra, MD, Fernando Oto Balieiro, MD, and Fernando Souza Leão, MD, São Paulo, Brazil

Endoscopic sinus and skull base surgery (ESSS) is considered the “gold standard” for the treatment of many lesions of the nose, paranasal sinus, and adjacent structures. The manipulation of instruments during these procedures is challenging because of the complex anatomy and proximity to important structures such as the brain, orbital content, carotid arteries, and optic nerve, among others.¹

Long periods of training are traditionally necessary in order to perform safe and adequate ESSS. Resident training includes anatomic lectures, a video session, cadaver dissection, direct observation of surgeries, and the realization of ESSS supervised by experienced doctors. Unfortunately, in some training hospitals, this process has been impaired by the restricted number of procedures and more difficult dissection pieces.^{1,2}

In order to fulfill this problem, virtual simulators have been developed. These simulators use virtual-reality concepts and direct interaction mechanisms with users, such as simulation of force and feedback of touch sensation on specific structures.^{1,3-5}

Unfortunately, these virtual models have some disadvantages, such as the high cost of the equipment, the use of computer-generated virtual images, some with low resolution, and touch-sensitive alterations in some structures. In addition, they do not allow the use of real instruments used on ESSS.

There is a general consensus that the size and complexity of the structures in the nose and paranasal sinus are a major problem in the development and construction of a real-simulation model for ESSS.¹

We show the development of a real model for training ESSS that allows the use of the same endoscopes and instruments used on real nasal procedures, discussing its steps, materials, and technical difficulties.

BUILDING THE MODEL

In conjunction with the company Pro Delphus (www.prodelphus.com.br) from Recife, Brazil, anatomic models were created based on pictures of anatomic structures, CT scans, and videos of endoscopic anatomic dissections in cadavers. Because of the nature of this project, no institutional review board approval was necessary.

The first step was the creation of the bony lateral nasal wall. This was done with a special resin simulating the human bone and had frontal sinus and recess, frontal beak, some ethmoid cells, opening for the placement of the maxillary sinus and lamina papyracea, and anterior sphenoid wall, among others. A bur was used in some parts in order to remove sharp edges or to thin specific spots, such as the sellar wall at the sphenoid sinus.

The second part was covering the bony lateral nasal wall with the Neoderma (Pro Delphus, Recife, Brazil) material.

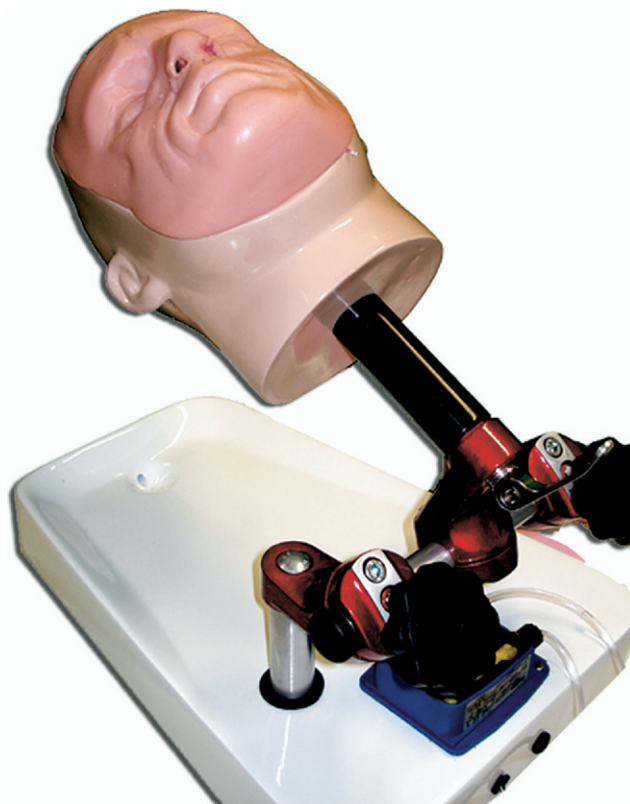


Figure 1 The Neoderma head over a developed holder.

Received May 15, 2008; accepted July 10, 2008.

This company developed special material simulating the consistency of the mucosa and soft tissues. The septum, turbinates, uncinata process, and other soft-tissue structures were separately created with the Neoderma and the resin. The third step was the positioning of these separately made structures with special glue.

Afterward, two completed nasal lateral walls were fixed together. The maxillary sinus cavity was placed, and a Neoderma face was attached. A holder for the head was developed to allow the fixation and mobility of the model (Fig 1).

Seven models were created, each with these anatomic structures: (1) nasal septum; (2) inferior, middle, and superior turbinates; (3) uncinata process; (4) lamina papyracea; (5) maxillary, frontal, ethmoidal, and sphenoidal sinus; (6) ethmoid bulla; (7) orbital content; (8) intersinus septum at the sphenoid sinus; and (9) sella with pituitary tumor.

CT scans and dissections were performed and recorded. The images were compared with dissections in cadavers and CT scans of humans, and a remarkable similarity was found (Fig 2).

DISCUSSION

One technical difficulty was the limited space and complex anatomy, such as nasal septum, turbinates, uncinata process, ethmoid bulla, paranasal sinus, and surrounding structures. The solution was to build the nasal lateral walls separately, attaching some structures at each wall. The turbinates, uncinata process, ethmoid bulla, other ethmoid cells, lamina papyracea, intersinus sphenoid septum, and pituitary tumor were glued or placed after. Another challenge was to make the natural ostia of maxillary and sphenoid sinus in a way to allow enlargement.

The model has essentially two parts: external and internal. The external part can be used as many times as necessary and is composed of a Neoderma human face with the two openings for the nostrils. The internal part can only be

dissected one time. After the dissection, the structure can be sent to the company for refurbishing of the structures and a further dissection can be done.

Some diseases, such as paranasal cysts, tumors, or others, can be constructed. This model allows the dissection using the same instruments and endoscopes used in real surgeries. Doctors with different levels of experience in ESSS dissected the models, and positive reactions were found regarding the use of real instruments. Of course, more studies of validation will be done in order to show another positive aspect of this model.

This model, named S.I.M.O.N.T. (Sinus Model Otorrino-Neuro Trainer, Recife, Brazil), has the capability to teach several endoscopic nasal procedures, such as septoplasty, turbinate surgery, paranasal sinus, and pituitary tumor surgery.

Currently, a new version of the model is being developed, with more anatomic structures such as agger nasi cells, optic nerve, internal carotid, ethmoidals, and sphenopalatine arteries with its branches out of the sphenopalatine foramen with bleeding capability in able to perform more procedures and an even more realistic experience.

AUTHOR INFORMATION

From the Sao Paulo ENT Center, Hospital Professor Edmundo Vasconcelos, São Paulo, Brazil.

Corresponding author: João Flávio Nogueira Jr, MD, Rua Martiniano de Carvalho, 1049 AP 195 C, São Paulo, SP, Brazil.

E-mail address: joaoflavioce@hotmail.com.

AUTHOR CONTRIBUTIONS

João Flávio Nogueira, writer, study design; **Aldo Cassol Stamm**, writer, study design; **Marcos Lyra**, data collection; **Fernando Oto Balieiro**, data collection; **Fernando Souza Leão**, data collection.

FINANCIAL DISCLOSURE

None.

REFERENCES

1. Arora H, Uribe J, Ralph W, et al. Assessment of construct validity of the endoscopic sinus surgery simulator. *Arch Otolaryngol Head Neck Surg* 2005;131:217–21.
2. Nogueira JF Jr, Baraúna Filho I, Hermann D, et al. Stereoscopic tridimensional images of the anatomy of the temporal bone: acquisition and demonstration. *Int Arch Otorhinolaryngol* 2008;12:105–10.
3. Fried M, Sadoughi B, Weghorst S, et al. Construct validity of the endoscopic sinus surgery simulator. *Arch Otolaryngol Head Neck Surg* 2007;133:350–7.
4. Glaser A, Hall C, Uribe J, et al. The effects of previously acquired skills on sinus surgery simulator performance. *Otolaryngol Head Neck Surg* 2005;133:525–30.
5. Edmond C Jr. Impact of the endoscopic sinus surgical simulator on operating room performance. *Laryngoscope* 2002;112:1148–58.

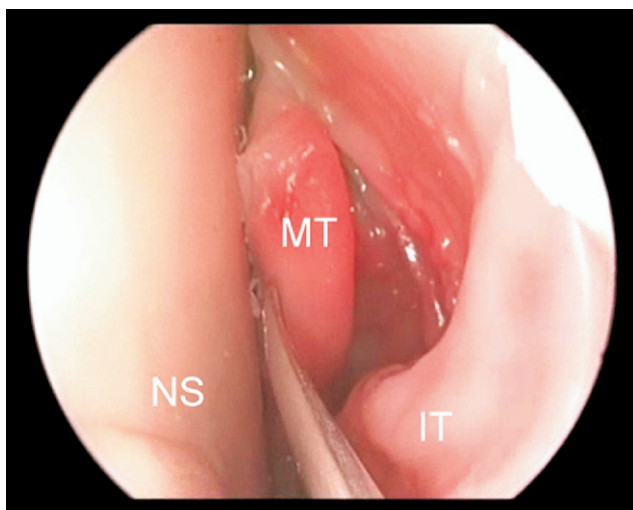


Figure 2 Nasal endoscopy of S.I.M.O.N.T. MT, middle turbinate; NS, nasal septum; IT, inferior turbinate.